

Contents lists available at [ScienceDirect](https://www.sciencedirect.com)

Journal of Oral and Maxillofacial Surgery, Medicine, and Pathology

journal homepage: www.journals.elsevier.com/journal-of-oral-and-maxillofacial-surgery-medicine-and-pathology

Original research

Metastatic tumors in the oral and maxillofacial region: A multicenter retrospective investigation in Japan

Shin-ichi Yamada^{a,*}, Takumi Hasegawa^b, Takashi Niiyama^c, Hironori Sakai^d,
Tomofumi Naruse^e, Koichi Koizumi^f, Kenichiro Uchida^g, Kotaro Sakurai^a,
Yoshio Ohyama^h, Yoshihide Otaⁱ, Kenichiro Ishibashi^j, Hirokazu Nakahara^{k,l},
Yuya Denda^m, Nobuhiro Yamakawaⁿ, Yukari Tasaka^o, Kazuma Noguchi^p, Akihisa Horie^q,
Tetsuya Nitta^r, Masahiro Nishimura^s, Wataru Kakuguchi^t, Toru Inomata^u,
Yoshiko Yamamura^v, Seiji Asoda^w, Japan Oral Oncology Group

^a Department of Oral and Maxillofacial Surgery, Faculty of Medicine, Academic Assembly, University of Toyama, Japan^b Department of Oral and Maxillofacial Surgery, Kobe University Graduate School of Medicine, Japan^c Department of Clinical Oral Oncology, NHO, Hokkaido Cancer Center, Japan^d Department of Dentistry and Oral Surgery, Shinshu University School of Medicine, Japan^e Department of Oral Maxillofacial Surgery, Graduate School of Biomedical Sciences, Nagasaki University, Japan^f Department of Oral Oncology, Graduate School of Biomedical and Health Sciences, Hiroshima University, Japan^g Department of Oral and Maxillofacial Surgery, Yamaguchi University Graduate School of Medicine, Japan^h Oral and Maxillofacial Surgery, Shizuoka City Shizuoka Hospital, Japanⁱ Department of Oral and Maxillofacial Surgery, Division of Surgery, Tokai University School of Medicine, Japan^j Department of Oral and Maxillofacial Surgery, Nagoya City University Graduate School of Medical Sciences, Japan^k Department of Dentistry and Oral Surgery, Osaka Metropolitan University Graduate School of Medicine, Japan^l Asahi University, Faculty of Dentistry, Department of Oral Pathology, Japan^m Department of Oral Surgery, Nagano Red Cross Hospital, Japanⁿ Department of Oral and Maxillofacial Surgery, Nara Medical University, Japan^o Department of Oral and Maxillofacial Surgery, Wakayama Medical University, Japan^p Department of Oral & Maxillofacial Surgery, School of Medicine, Hyogo Medical University, Japan^q Department of Oral and Maxillofacial Surgery, Kanto Rosai Hospital, Japan^r Department of Oral Surgery, Kagoshima City Hospital, Japan^s Department of Dentistry and Oral Surgery, Nagano Municipal Hospital, Japan^t Oral and Maxillofacial Surgery, Division of Oral Pathobiological Science, Faculty of Dental Medicine and Graduate School of Dental Medicine, Hokkaido University, Japan^u Department of Oral and Maxillofacial Surgery, Nippon Dental University, Japan^v Department of Oral Surgery, Oral Sciences, Clinical Dentistry, Institute of Biomedical Sciences, Tokushima University Graduate School, Japan^w Department of Dentistry and Oral Surgery, Keio University School of Medicine, Japan

ARTICLE INFO

Keywords:

metastatic tumor
molecular targeted drug
immune checkpoint inhibitor
resection

ABSTRACT

Background/purpose: Metastatic tumors in the oral and maxillofacial region are rare. The purpose of this study was to investigate the incidence and prognosis of this entity based on a multicenter retrospective analysis.

Materials and methods: The medical records of patients with metastatic tumors to the oral and maxillofacial region were retrospectively reviewed, and 81 patients with such metastatic tumors were included in this study. The incidence and prognosis of the patients were investigated as endpoints of this study.

Results: The male to female ratio was 1.8–1. The patients' mean age was 67.4 ± 12.4 years old. The most common primary site was the lungs (25.9 %). As for the metastatic sites in the oral and maxillofacial region, the most

Abbreviations: ICI, immune checkpoint inhibitors; QOL, quality of life; OS, overall survival; PD-1, programmed cell death protein 1; PD-L1, programmed death-ligand 1; CTLA-4, cytotoxic T-lymphocyte associated protein 4; NSCLC, non-small-cell lung cancer; EGFR, epidermal growth factor receptor; TKI, tyrosine kinase inhibitor; ALK, anaplastic lymphoma kinase; HER2, human epidermal growth factor receptor 2; HR, hazard ratio; CI, confidence interval.

* Correspondence to: Department of Oral and Maxillofacial Surgery, Faculty of Medicine, Academic Assembly, University of Toyama, 2630, Sugitani, Toyama 930-0194, Japan

E-mail address: shinshin@med.u-toyama.ac.jp (S.-i. Yamada).

<https://doi.org/10.1016/j.ajoms.2026.02.008>

Received 13 September 2025; Received in revised form 23 January 2026; Accepted 13 February 2026

Available online 16 February 2026

2212-5558/© 2026 Asian AOMS, JSOP, JSOMS, JAOM, JAMI, and JSTMJ. Published by Elsevier Ltd. All rights are reserved, including those for text and data mining, AI training, and similar technologies.

common site was the lower gingiva (35.8 %). Adenocarcinoma was the most common diagnosis (37.0 %). The administration of molecular targeted drugs and immune checkpoint inhibitors (ICIs) showed the tendency of better control compared with the non-administration of these drugs. The local resection of the metastatic tumor resulted in significantly better metastatic lesion control than other treatments (HR: 0.259, 95 %CI: 0.103–0.650 $P < 0.01$).

Conclusion: The survival period of patients with metastatic tumors in the oral and maxillofacial region tended to be longer in cases treated with molecular targeted drugs and ICIs. The resection of metastatic tumors in the oral and maxillofacial region may be more effective at controlling the disease, which may contribute to maintaining QOL.

1. Introduction

Malignant tumors arising in the oral cavity account for 5–6 % of all human cancers [1]. Metastasis to the oral and maxillofacial region from other sites of the body is very rare and accounts for about 1 % of malignant tumors arising in this region [2–4]. Many cases of metastatic tumors in the oral and maxillofacial region also involve other distant metastatic lesions; i.e., disseminated disease, resulting in a poor prognosis [2,3,5,6].

Metastatic oral and maxillofacial tumors are more common in males and most commonly arise between the fifth and seventh decades of life [6–8]. Regarding the clinical symptoms of metastatic tumors in the oral and maxillofacial region, they can look like benign lesions, such as inflammatory and hyperplastic lesions that look like pyogenic granuloma or epulis [7,9,10]. The jawbone is a more common site of metastasis within the oral cavity than the soft tissue, and the posterior portion of the mandible is the most common site [8,11,12]. Among primary malignant tumors, lung tumors metastasize to the oral and maxillofacial region most frequently, followed by breast and kidney tumors [11,13,14].

The prognosis of patients with metastatic tumors in the oral and maxillofacial region is poor. In previous studies, the mean survival period was 7–8 months [6,8,10]. However, advances in cancer immunotherapy and molecular targeted drugs have significantly improved clinical outcomes across various malignancies [15–20]. These therapies may improve the survival time and the quality of life (QOL) of patients with metastatic tumors in the oral and maxillofacial region. On the other hand, the effects of these therapies in these patients remain unclear.

The purpose of this study was to investigate the incidence and prognosis of metastatic tumors in the oral and maxillofacial region based on a multicenter retrospective analysis conducted in Japan. The treatment outcomes of such tumors were also examined.

2. Patients and methods

2.1. Patients

The ethics committee of the University of Toyama approved the study protocol (No. R2022185). We published a research plan and guaranteed that an opt-out opportunity would be provided on the homepage of each hospital that participated in the study.

The medical records of patients with metastatic tumors in the oral and maxillofacial region who were diagnosed at one of 23 institutions in Japan (Kobe University, Hokkaido Cancer Center, Shinshu University, Nagasaki University, Hiroshima University, Yamaguchi University, Shizuoka City Shizuoka Hospital, Tokai University, Nagoya City University, Osaka Metropolitan University, Nagano Red Cross Hospital, Nara Medical University, Wakayama Medical University, Hyogo College of Medicine, Keio University, Shinshu University, Kanto Rosai Hospital, Nippon Dental University, Hokkaido University, Tokushima University, Nagano Municipal Hospital, Kagoshima City Hospital and the University of Toyama) between January 2008 and March 2022 were retrospectively reviewed, and 81 patients were included in this study.

2.2. Data collection

Information regarding age; sex; the primary tumor site; the site of metastasis; the clinical features of the metastatic tumor; the histopathological diagnosis; the time between the diagnosis of the primary tumor and the metastatic tumor; treatment strategies, including the administration of molecular targeted drugs or immune checkpoint inhibitors (ICIs); and outcomes were extracted from the subjects' medical records. The following definition of metastatic tumors in oral and maxillofacial region, which was reported by Clausen et al. [5], was used: the presence of a clinically and histologically confirmed primary tumor located outside the oral cavity; the presence of a jaw or oral tumor that is recognized as a metastatic lesion; histological similarity between the primary tumor and the metastatic lesion; a distinct boundary between the primary and metastatic sites, with no evidence of direct invasion; and no history of a primary tumor originating within the oral cavity. The endpoints of this study were the incidence rate of metastatic tumors, the overall survival (OS) rate, and the relationship between treatment strategies, including the use of molecular targeted therapy and ICIs, and prognosis in Japanese populations.

2.3. Statistical analysis

Statistically, univariate analyses were performed using Fisher's exact test. The OS was calculated with Kaplan-Meier curves. The log-rank test was used to test the significance of differences between Kaplan-Meier curves. A multivariate analysis was performed with Cox proportional hazard model. All statistical analyses were conducted using JMP® 13.0 (SAS Institute Inc., Cary, NC, USA). P-values of less than 0.05 were considered to indicate significance.

3. Results

In this study, 81 patients with metastatic tumors in the oral and maxillofacial region were investigated. Since there were 11,404 primary malignant tumors arising in the oral and maxillofacial region during the study period, the incidence of metastatic tumors in the oral and maxillofacial region was 0.7 % (81/11,404 cases). The characteristics of the patients are summarized in Table 1 (Table 1). There were 52 male patients (64.2 %) and 29 female patients (35.8 %), giving a male to female ratio of 1.8–1. The patients' mean age was 67.4 ± 12.4 years old (range, 20–88 years). The most common primary site was the lungs (21 cases, 25.9 %), followed by the kidneys/prostate/bladder (20 cases, 24.7 %), colon (10 cases, 12.3 %), liver and bile duct (8 cases, 9.9 %), and breast (7 cases, 8.6 %). As for the metastatic sites, the most common site was the lower gingiva (29 cases, 35.8 %), followed by the upper gingiva (21 cases, 25.9 %), mandibular bone (20 cases, 24.7 %), and tongue (6 cases, 7.4 %). Regarding the histopathological types of tumor, there were 69 cases (85.2 %) of carcinoma and 12 (14.8 %) of sarcoma. Adenocarcinoma was the most common diagnosis (30 cases, 37.0 %), followed by renal cell carcinoma (15 cases, 18.5 %) and hepatocellular carcinoma or squamous cell carcinoma (6 cases each, 7.4 %). The most common clinical feature of the metastatic tumors was mass formation (42 cases, 51.9 %), followed by swelling (28 cases, 34.6 %), pain (22 cases,

Table 1

The characteristics of patients with metastatic tumors in the oral and maxillofacial region (n = 81).

Variables	Case No. (%)	Variables	Case No. (%)
Gender		Metastatic site in OMFR	
Female	29 (35.8)	Lower gingiva	29 (35.8)
Male	52 (64.2)	Upper gingiva	21 (25.9)
Age (years)	67.4 ± 12.4	Mandibular bone	20 (24.7)
(mean, SD) (range)	20–88	Tongue	6 (7.4)
Primary site		Palate	3 (3.7)
Lung	21 (25.9)	Buccal mucosa	1 (1.2)
Kidney, prostate, or bladder	20 (24.7)	Lower lip	1 (1.3)
Colon	10 (12.3)	Clinical features of metastatic lesions (overlapping)	
Liver or bile duct	8 (9.9)	Mass formation	42 (51.9)
Breast	7 (8.6)	Swelling	28 (34.6)
Esophagus	4 (4.9)	Pain	22 (27.2)
Lower leg	4 (4.9)	Bleeding	10 (12.3)
Thyroid	2 (2.5)	Hypoesthesia	10 (12.3)
Others	5 (6.2)	Ulceration	5 (6.2)
Histopathological type		Tooth mobility	1 (1.2)
Adenocarcinoma	30 (37.0)	Nothing	2 (2.5)
Renal cell ca.	15 (18.5)		
Hepatocellular ca.	6 (7.4)		
Squamous cell ca.	6 (7.4)		
Invasive ductal ca.	5 (6.2)		
Urothelial ca.	3 (3.7)		
Non-small cell ca.	2 (2.5)		
Others	14 (17.3)		
Variables	Case No. (%)		
Treatment for primary tumor			
Chemotherapy	23 (29.1)		
Surgery+chemotherapy	19 (26.0)		
Surgery	16 (19.0)		
Best supportive care	10 (11.4)		
Surgery+chemoradiotherapy	5 (6.3)		
Chemoradiotherapy	5 (6.3)		
Surgery+radiotherapy	3 (3.8)		
Use of molecular targeted drugs and ICIs			
Yes	29 (36.7)		
No	52 (63.3)		
Primary tumor diagnosed first	63 (77.8)		
Metastasis to OMFR diagnosed first	18 (22.2)		
Incidence of metastasis to OMFR	0.70 %		
	81/11,404 cases		
Period of metastasis in OMFR (months)	43.1 ± 53.7		
(mean, SD) (range)	(0.5–228)		
Observation period (months)	50.3 ± 53.9		
(mean, SD) (range)	(1–240)		

Ca: carcinoma

ICI: immune checkpoint inhibitor

OMFR: oral and maxillofacial region

SD: standard deviation

27.2 %), and bleeding or hypoesthesia (10 cases each, 12.3 %).

The mean observation period was 43.1 ± 53.7 months (range, 1–240 months). In 63 patients (77.8 %), the primary tumor was diagnosed before the metastasis to the oral and maxillofacial region and the mean time between these diagnoses was 43.1 ± 53.7 months (range, 0.5–228 months). In 18 patients (22.2 %), the metastatic tumors in the oral and maxillofacial region were diagnosed first.

The 5-year OS of all patients in whom the primary tumor was diagnosed first was 42.1 % (median, 53 months) (Fig. 1). On the other hand, the 5-year OS rate of the patients in whom the metastatic tumor was diagnosed before the primary tumor was 12.1 % (median, 10 months). In this study, molecular targeted drugs and ICIs were administered to 29 patients (36.7 %). Among the patients in whom the primary tumor was diagnosed first, the 5-year OS rate was 56.8 % (median, 76 months) for the patients treated with molecular targeted drugs and ICIs, whereas it was 34.0 % (median, 24 months) for those who were not given these

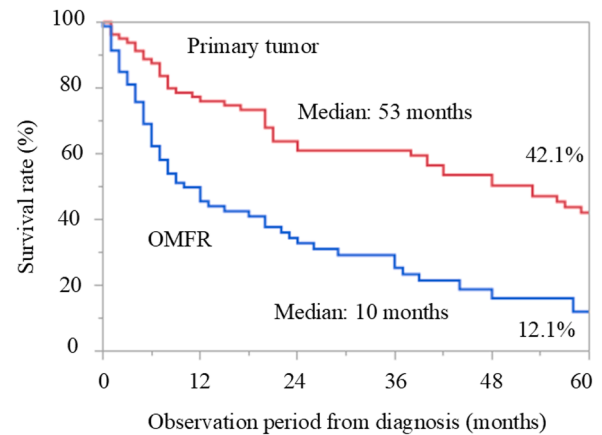


Fig. 1. Overall survival of patients with metastatic tumors in the oral and maxillofacial region. The 5-year overall survival rate of the patients in whom the primary tumor was diagnosed before the metastatic tumor was 42.1 %. The 5-year overall survival rate of the patients in whom the metastatic tumor was diagnosed before the primary tumor was 12.1 %. OMFR: oral and maxillofacial region.

drugs (log-rank test: $p = 0.051$) (Fig. 2). Among the patients in whom the metastatic tumor was diagnosed first, the 5-year OS rates were 25.5 % (median, 20 months) for the patients treated with molecular targeted drugs and ICIs and 8.5 % (median, 9 months) for the patients that were not given these drugs (log-rank test: $p = 0.057$) (Fig. 3).

The administration of molecular targeted drugs and ICIs resulted in significantly improved disease control compared with the non-administration of these drugs (Fisher's exact test, $P < 0.05$) (Table 2). However, a multivariate analysis for OS revealed no significant prognostic factor, including the administration of molecular targeted drugs and ICIs (date not shown).

The local resection of metastatic tumors in oral and maxillofacial region was performed in 21 patients (25.9 %) (Table 3). The local resection of the metastatic tumors resulted in significantly better metastatic lesion control than other treatments (Fisher's exact test, $P < 0.01$). A multivariate analysis revealed that local resection of metastatic tumor in OMFR (Hazard ratio (HR): 0.259, 95 % confidence interval (CI): 0.103–0.650, $P < 0.01$), together with primary site tumor

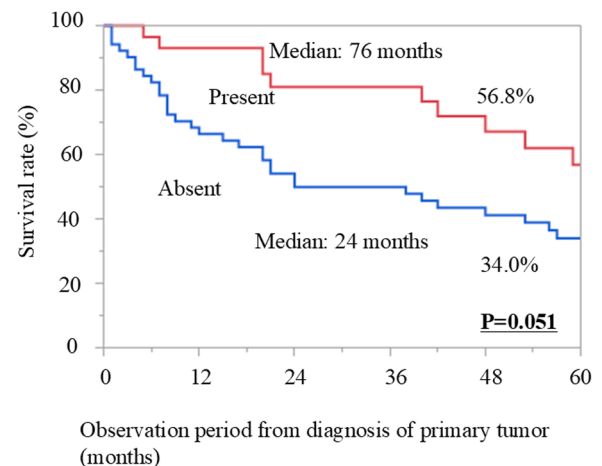


Fig. 2. Overall survival from the diagnosis of the primary tumor according to the presence/absence of molecular targeted drug and immune checkpoint inhibitor treatment. Among the patients in whom the primary tumor was diagnosed before the metastatic tumor, the 5-year overall survival rate was 56.8 % and 34.0 % for the patients that were and were not treated with molecular targeted drugs and immune checkpoint inhibitors, respectively (log-rank test: $p = 0.051$).

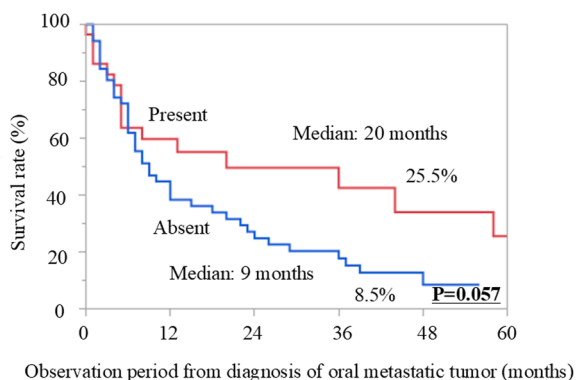


Fig. 3. Overall survival from the diagnosis of the oral metastatic tumor according to the presence/absence of molecular targeted drug and immune checkpoint inhibitor treatment. Among the patients in whom the metastatic tumor was diagnosed before the primary tumor, the 5-year overall survival rate was 25.5 % and 8.5 % in the patients that were and were not treated with molecular targeted drugs and immune checkpoint inhibitors, respectively (log-rank test: $p = 0.057$).

Table 2
Prognosis according to the presence/absence of molecular targeted drug and immune checkpoint inhibitor treatment.

Prognosis	Present	Absent	Total (%)
Died of metastatic failure	13 (16.0)	25 (30.9)	38 (46.9)
Died of local failure	4 (5.0)	17 (21.0)	21 (25.9)
Alive with disease	10 (12.3)	9 (11.1)	19 (23.5)
Alive without disease	2 (2.5)	1 (1.2)	3 (3.7)
Control of disease	12 (14.8)	10 (12.3)	22 (27.2)
No control of disease	17 (21.0)	42 (51.9)	59 (72.8)
			$P < 0.05^*$

* Fisher's exact test

control (HR: 0.215, 95 % CI: 0.0984–0.468, $P < 0.001$) and metastasis to OMFR after diagnosis of primary tumor (HR: 2.926, 95 % CI: 1.271–6.737, $P < 0.05$), was significant independent factor of control of metastatic tumor in OMFR (Table 4).

4. Discussion

Recent advances in therapeutic modalities, especially anti-tumor drugs, such as molecular targeted drugs and ICIs, have improved the QOL and prognosis of patients suffering from malignancies. The purpose of this study was to investigate the clinical characteristics and prognosis of metastatic tumors in the oral and maxillofacial region in Japanese patients based on a multicenter study. The incidence of metastatic tumors in the oral and maxillofacial region was 0.7 %. The prognosis of patients with advanced malignancies, including metastatic tumors in the oral and maxillofacial region, may be improved by the administration of molecular targeted drugs and ICIs in a univariate analysis. The local resection of metastatic tumors in the oral and maxillofacial region may result in better control of such metastatic tumors.

The incidence of metastatic tumors in the oral and maxillofacial region has been reported to be about 1.0 % among oral malignancies

Table 3
Treatments and prognosis of metastatic tumors in OMFR.

Prognosis	Observation	Chemoradiotherapy/radiotherapy	Chemotherapy	Reduction	Resection
Controlled	8 (9.9)	7 (1.2)	7 (8.6)	0 (0)	21 (25.9)
Uncontrolled	19 (23.5)	9 (0)	2 (2.5)	2 (2.5)	6 (7.4)
		uncontrolled	Controlled		
			P-value		
Resection	6 (7.4)	21 (25.9)			
Non-resection	32 (39.5)	22 (27.2)			
			$P < 0.01$		

[2–4]. In this study, the incidence of metastatic tumors was 0.7 %, which was lower than in previous studies. However, there are many cases in which it was not possible to confirm the diagnosis with a biopsy due to systemic problems or the wishes of the patient or their family. In this study, the incidence rate of such metastatic tumors may have been lower than previously reported because the eligibility criteria included a histopathological match between the primary and metastatic tumors. Japanese society is a super-aged society, with 28.1 % of the population being elderly (65 years or older) in 2018 [21,22]. Therefore, the incidence of metastatic tumors in the oral and maxillofacial region may increase in the future. In addition, it is expected that the incidence rate will increase from this report, as biopsies cannot be performed due to aging and deterioration of the patient's general condition due to the primary tumor or distant metastasis, and there will be an increase in cases where distant metastasis is diagnosed clinically.

This study revealed a higher incidence of metastatic tumors in the oral and maxillofacial region in males than in females, and this agrees with previous reports that showed male-female ratios ranging from 1.2:1–2:1 [8,9,23]. In the present study, the most common primary tumor site was the lungs, followed by the renal and urinary system, and the colon. In males, the lung was most common primary tumor site (14 cases), and in females it was the breast and colon (7 cases each) (data not shown). According to Global Cancer Statistics 2020 [24], lung cancer was the second most common diagnosed cancer and the most common cause of cancer-related death in 2020. In males, lung neoplasms were the most common cause of cancer-related morbidity and mortality [24]. In females, the incidence of lung cancer ranked third after breast and colorectal cancers, and lung cancer was ranked second for mortality after breast cancer [24]. The incidence of metastatic tumors in the oral and maxillofacial region was reported to be consistent with the occurrence of primary tumors and to reflect differences in the biological components of those tumors [6]. Cancers arising in the kidneys, liver, and lungs were reported to exhibit a tendency to metastasize to the buccomaxillofacial region [9]. The trends in primary tumors seen in the present study were generally similar to those described in previous

Table 4
Multivariate analysis of prognosis of metastatic tumors in OMFR.

Variable	HR	95%CI	P value
Age	1.001	0.974–1.031	–
Gender			
Male vs Female	0.923	0.454 - 1.873	NS(P = 0.824)
Control of primary tumor			
Controlled vs Uncontrolled	0.215	0.0984–0.468	$P < 0.001$
Use of molecular targeted drugs and ICIs			
Yes vs No	0.751	0.363–1.551	NS ($p = 0.439$)
Treatment for metastasis of OMFR			
Resection vs Non-resection	0.259	0.103–0.650	$P < 0.01$
Metastasis to OMFR diagnosed first			
Yes vs No	2.926	1.271–6.737	$P < 0.05$

OMFR: oral and maxillofacial region

ICI: immune checkpoint inhibitor

HR: hazard ratio

CI: confidence interval

NS: Not significant

studies.

Regarding the correlations between primary sites and metastatic sites in the oral and maxillofacial region, breast cancer was reported to metastasize twice as frequently to the jawbones than soft tissues, whereas lung and kidney cancers tend to metastasize to soft tissues [6, 23,25,26]. A correlation was reported between sex and bone and soft-tissue metastasis [8]. In the current study, the lower gingiva was the most common metastatic site in the oral and maxillofacial region, followed by the upper gingiva and mandibular bone. Metastases to the lower gingiva and mandibular bone accounted for 60.5 % of metastatic tumors. Metastatic sites in the oral and maxillofacial region have been reported to be affected by inflammation of the gingiva and whether teeth are present [6,11,25,27]. In dentate patients, 79 % of oral metastases have been reported to occur in the gingiva, whereas in edentulous patients, metastasis to the tongue and alveolar mucosa is more common [28]. With aging, the amount of active hematopoietic bone marrow decreases, and hematopoietic bone marrow remains in the posterior part of the mandible. This hematopoietically active marrow region has been reported to act as a favorable niche for metastasis [6].

The prognosis of patients with metastatic tumors in the oral and maxillofacial region has been reported to be poor, with a mean survival of 7–8 months [6,8,10]. In this study, the median survival period of all patients in whom the primary tumor was diagnosed before the metastatic tumor was 53 months, whereas that of the patients in whom the metastatic tumor was diagnosed first was 10 months. Recent advances in treatment modalities, especially molecular targeted drugs and ICIs, may improve the prognosis of patients with metastatic tumors. ICIs, such as antibodies targeting programmed cell death protein 1 (PD-1), programmed death-ligand 1 (PD-L1), and cytotoxic T-lymphocyte associated protein 4 (CTLA-4), have transformed the treatment of metastatic cancers. In metastatic non-small-cell lung cancer (NSCLC), pembrolizumab significantly prolonged OS in patients with high PD-L1 expression compared with chemotherapy alone [29]. Similarly, combined nivolumab and ipilimumab therapy has demonstrated long-term benefits in patients with advanced melanoma [30] and renal cell carcinoma [31]. In parallel, molecular targeted therapies have provided effective treatment options based on specific genetic alterations. Osimertinib, a third-generation epidermal growth factor receptor (EGFR) tyrosine kinase inhibitor (TKI), has shown superior progression-free survival in EGFR-mutated metastatic NSCLC than earlier-generation TKIs [32]. Likewise, alectinib has demonstrated significant survival benefits over crizotinib in patients with anaplastic lymphoma kinase (ALK)-positive metastatic NSCLC [33]. In human epidermal growth factor receptor 2 (HER2)-positive metastatic breast cancer, dual HER2 blockade with pertuzumab and trastuzumab combined with docetaxel significantly improved OS [34].

In the current study, a univariate analysis revealed that the survival rate tended to be longer in patients who were treated with molecular targeted drugs or ICIs than in those who were not. A multivariate analysis also showed that the administration of molecular targeted drugs or ICIs (date not shown). The subjects in this study included many recent cases, and it is presumed that advances in treatment modalities, such as molecular targeted drugs and ICIs, have led to improvements in survival times. However, there were no characteristic events in the group that used these drugs (Table 5), which is thought to be due to the small number of cases in which these drugs were used and differences in the timing of their use.

In addition, metastatic lesions were controlled to a significantly greater degree in cases in which metastatic lesions in the oral and maxillofacial region were resected. When the primary lesion and other metastatic lesions are controlled and resection is possible in terms of the patient's overall condition, resection is effective and is presumed to lead to the maintenance of QOL. The results of a multivariate analysis in this study might support this. Although the participants of this study were small number, seven cases were controlled with drug therapy, suggesting that drug therapy may be useful for controlling metastatic lesions.

Table 5

The characteristics of patients administrated molecular targeted drugs and ICIs.

Variables	No. (%)	Variables	No. (%)	Variables
Gender		Metastatic site in OMFR		Prognosis
Female	9 (31.0)	Lower gingiva	10 (34.5)	Died of metastatic failure
Male	20 (69.0)	Upper gingiva	9 (31.0)	Alive with disease
Age(years)	66.4 ± 11.5	Mandibular bone	8 (27.6)	Died of local failure
(mean, SD) (range)	(42 - 88)	Tongue	2(6.9)	Alive without disease
Primary site		Treatment for primary tumor		
Kidney	10 (34.5)	Chemotherapy	11 (37.9)	
Lung	8 (27.6)	Surgery + chemotherapy	7 (24.1)	
Colon	4 (13.8)	Surgery	6 (20.7)	
Liver	3 (10.3)	Surgery + chemoradiotherapy	3 (10.3)	
Esophagus	2(6.9)	Chemoradiotherapy	1(3.4)	
Breast	1(3.4)	Best supportive care	1(3.4)	
Bladder	1(3.4)	Treatment for metastatic tumor in OMFR		
Histopathological type		Resection	9 (31.0)	
Renal cell ca.	10 (34.5)	Observation	9 (31.0)	
Adenocarcinoma	7 (24.1)	Radiotherapy	5 (17.2)	
Squamous cell ca.	3 (10.3)	Chemotherapy	3 (10.3)	
Hepatocellular ca.	3 (10.3)	Reduction	2(6.9)	
Mesothelioma	2(6.9)	Chemoradiotherapy	1(3.4)	
Urothelial ca.	1(3.4)	Prognosis of metastatic tumor in OMFR		
Non-small cell ca.	1(3.4)	Controlled	15 (51.7)	
Spindle sarcoma	1(3.4)	Uncontrolled	14 (48.3)	
Angiosarcoma	1(3.4)			

Ca: carcinoma

ICI: immune checkpoint inhibitor

OMFR: oral and maxillofacial region

SD: standard deviation

However, further study based on more cases will be needed.

The main strength of this study was the fact that it investigated the clinical factors and prognosis of elderly Japanese patients with metastatic tumors in the oral and maxillofacial region, based on a relatively large number of patients and a multicenter approach. On the other hand, the main limitation of this study was its retrospective nature. In this study, since specific molecular profiles were not investigated, the effects of these agents target specific molecular abnormalities, presenting the underlying molecular diagnosis for effective treatment, to the extent possible, remains unknown.

In addition, the recent advances in molecular targeted drugs, ICIs, and radiotherapy, such as the Quad Shot regimen, are expected to have beneficial clinical impacts on oral cancer patients who are not candidates for the standard curative treatment [35,36]. However, because multidisciplinary treatment is used in advanced cancer, it is difficult to accurately assess the effectiveness of each treatment. Therefore, a further prospective study focused on the effectiveness of molecular targeted drugs and ICIs in patients with metastatic tumors in the oral and

maxillofacial region will be needed.

5. Conclusion

In conclusion, the incidence of metastatic tumors in the oral and maxillofacial region was 0.7 %. The survival period of patients with such metastatic tumors tended to be longer in cases treated with molecular targeted drugs and ICIs. If the patient's general condition permits, it is suggested that resecting metastatic tumors in the oral and maxillofacial region may be more effective at controlling the disease, leading to the maintenance or improvement of QOL.

Declaration of Competing Interest

The authors declare that they have no conflicts of interest associated with this manuscript.

Acknowledgments

This study was conducted with the cooperation of the following researchers. We would like to express our deep thanks to: Umeda M (Nagasaki University), Akashi M (Kobe University), Kurita H (Shinshu University), Itoh N (Hiroshima University), Yanamoto S (Hiroshima University), Kirita T (Nara Medical University), Yoshimura H (Fukui University), Sasaki M (Tokai University), Tomihara K (Niigata University), Kumagai K (Tokyo University), Shibuya Y (Nagoya City University), Ueda M (Hokkaido Cancer Center), Rin S (Hokkaido Cancer Center), Kamata K (Tokushima University), Ohno Y (Hokkaido University), Gouda Y (Ehime University), Uchida D (Ehime University), Sakurai A (Shinshu University), Yamada Y (Keio University), Koike T (Ina Central Hospital), Kajihara R (Shinshu University), Kondou E (Hakodate Central Hospital), Kishimoto H (Hyogo Medical University), Mishima K (Yamaguchi University), and Matsumura T (Wakayama Medical University). We wish to thank Medical English Service (<https://www.med-english.com/>) for their help with the English proofreading. This work was supported by Japan Society for the Promotion of Science (JSPS) KAKENHI Grant Number JP 24K13127.

References

- Maschino F, Guillet J, Curien R, Dolivet G, Bravetti P. Oral metastasis: a report of 23 cases. *Int J Oral Maxillofac Surg* 2013;42:164–8.
- Cash CD, Royer RQ, Dahlin DC. Metastatic tumors of the jaws. *Oral Surg Oral Med Oral Pathol* 1961;14:897–905.
- Meyer I, Shklar G. Malignant tumors metastatic to mouth and jaws. *Oral Surg Oral Med Oral Pathol* 1965;20:350–62.
- van der Waal RI, Buter J, van der Waal I. Oral metastases: report of 24 cases. *Br J Oral Maxillofac Surg* 2003;41:3–6.
- Clausen F, Poulsen H. Metastatic carcinoma of the jaws. *Acta Pathol Microbiol Scand* 1963;57:361–74.
- Hirshberg A, Berger R, Allon I, Kaplan I. Metastatic tumors to the jaws and mouth. *Head Neck Pathol* 2014;8:463–74.
- Nuyen BA, Tang CG. Gingival metastasis: a case report and literature review. *Perm J* 2016;20:71–3.
- Kirschnick LB, Schuch LF, Cademartori MG, Vasconcelos ACU. Metastasis to the oral and maxillofacial region: a systematic review. *Oral Dis* 2022;28:23–32.
- Shen ML, Kang J, Wen YL, Ying WM, Yi J, Hua CG, et al. Metastatic tumors to the oral and maxillofacial region: a retrospective study of 19 cases in West China and review of the Chinese and English literature. *J Oral Maxillofac Surg* 2009;67:718–37.
- Vasilyeva D, Peters SM, Philipone EM, Yoon AJ. Renal cell carcinoma metastatic to the maxillary gingiva: a case report and review of the literature. *J Oral Maxillofac Pathol* 2018;22:S102–7.
- McClure SA, Movahed R, Salama A, Ord RA. Maxillofacial metastases: a retrospective review of one institution's 15-year experience. *J Oral Maxillofac Surg* 2013;71:178–88.
- Gultekin SE, Senguvan B, Isik Gonul I, Okur B, Buettner R. Unusual presentation of an adenocarcinoma of the lung metastasizing to the mandible, including molecular analysis and a review of the literature. *J Oral Maxillofac Surg* 2016;74.
- Jham BC, Salama AR, McClure SA, Ord RA. Metastatic tumors to the oral cavity: a clinical study of 18 cases. *Head Neck Pathol* 2011;5:355–8.
- Murillo J, Bagan JV, Hens E, Diaz JM, Leopoldo M. Tumors metastasizing to the oral cavity: a study of 16 cases. *J Oral Maxillofac Surg* 2013;71:1545–51.
- Larkin J, Chiarion-Sileni V, Gonzalez R, Grob JJ, Cowey CL, Lao CD, et al. Combined nivolumab and ipilimumab or monotherapy in untreated melanoma. *N Engl J Med* 2015;373:23–34.
- Swain SM, Kim SB, Cortés J, Ro J, Semiglazov V, Campone M, et al. Pertuzumab, trastuzumab, and docetaxel for HER2-positive metastatic breast cancer. *N Engl J Med* 2015;372:724–34.
- Reck M, Rodríguez-Abreu D, Robinson AG, Hui R, Csószti T, Fülöp A, et al. Pembrolizumab versus chemotherapy for PD-L1-positive non-small-cell lung cancer. *N Engl J Med* 2016;375:1823–33.
- Peters S, Camidge DR, Shaw AT, Gadgeel S, Ahn JS, Kim DW, et al. Alectinib versus crizotinib in untreated ALK-positive non-small-cell lung cancer. *N Engl J Med* 2017;377:829–38.
- Motzer RJ, Tannir NM, McDermott DF, Arén Frontera O, Melichar B, Choueiri TK, et al. Nivolumab plus ipilimumab versus sunitinib in advanced renal-cell carcinoma. *N Engl J Med* 2018;378:1277–90.
- Soria JC, Ohe Y, Vansteenkiste J, Reungwetwattana T, Chewaskulyong B, Lee KH, et al. Osimertinib in untreated EGFR-mutated advanced non-small-cell lung cancer. *N Engl J Med* 2018;378:113–25.
- Cabinet Office. White paper on population aging (2019 version). (https://www8.cao.go.jp/kourei/whitepaper/w-2019/zenbun/01pdf_index.html) (accessed August 10, 2025) (in Japanese).
- Song P, Tang W. The community-based integrated care system in Japan: health care and nursing care challenges posed by super-aged society. *Biosci Trends* 2019;13:279–81.
- Hirshberg A, Shnaiderman-Shapiro A, Kaplan I, Berger R. Metastatic tumours to the oral cavity - pathogenesis and analysis of 673 cases. *Oral Oncol* 2008;44:743–52.
- Sung H, Ferlay J, Siegel RL, Laversanne M, Soerjomataram I, Jemal A, et al. Global cancer statistics 2020: GLOBOCAN estimates of incidence and mortality worldwide for 36 cancers in 185 countries. *CA Cancer J Clin* 2021;71:209–49.
- Allon I, Pessing A, Kaplan I, Allon DM, Hirshberg A. Metastatic tumors to the gingiva and the presence of teeth as a contributing factor: a literature analysis. *J Periodontol* 2014;85:132–9.
- Kaplan I, Raiser V, Shuster A, Shlomi B, Rosenfeld E, Greenberg A, et al. Metastatic tumors in oral mucosa and jawbones: unusual primary origins and unusual oral locations. *Acta Histochem* 2019;121:151448.
- Rai H. Oral Metastasis-A reason to expose the primary site -a short review. *Internet J Pathol* 2010;12:1–5.
- Hirshberg A, Leibovich P, Buchner A. Metastases to the oral mucosa: analysis of 157 cases. *J Oral Pathol Med* 1993;22:385–90.
- Reck M, Rodríguez-Abreu D, Robinson AG, Hui R, Csószti T, Fülöp A, et al. Pembrolizumab versus chemotherapy for PD-L1-positive non-small-cell lung cancer. *N Engl J Med* 2016;375:1823–33.
- Larkin J, Chiarion-Sileni V, Gonzalez R, Grob JJ, Cowey CL, Lao CD, et al. Combined nivolumab and ipilimumab or monotherapy in untreated melanoma. *N Engl J Med* 2015;373:23–34.
- Motzer RJ, Tannir NM, McDermott DF, Arén Frontera O, Melichar B, Choueiri TK, et al. Nivolumab plus ipilimumab versus sunitinib in advanced renal-cell carcinoma. *N Engl J Med* 2018;378:1277–90.
- Soria JC, Ohe Y, Vansteenkiste J, Reungwetwattana T, Chewaskulyong B, Lee KH, et al. Osimertinib in untreated EGFR-mutated advanced non-small-cell lung cancer. *N Engl J Med* 2018;378:113–25.
- Peters S, Camidge DR, Shaw AT, Gadgeel S, Ahn JS, Kim DW, et al. Alectinib versus crizotinib in untreated ALK-positive non-small-cell lung cancer. *N Engl J Med* 2017;377:829–38.
- Swain SM, Kim SB, Cortés J, Ro J, Semiglazov V, Campone M, et al. Pertuzumab, trastuzumab, and docetaxel for HER2-positive metastatic breast cancer. *N Engl J Med* 2015;372:724–34.
- Toya R, Saito T, Yamaguchi K, Matsuyama T, Watakabe T, Matsumoto T, et al. Hypofractionated palliative volumetric modulated arc radiotherapy with the radiation oncology study group 8502 "QUAD shot" regimen for incurable head and neck cancer. *Radiat Oncol* 2020;15:123.
- Grewal AS, Jones J, Lin A. Palliative radiation therapy for head and neck cancers. *Int J Radiat Oncol Biol Phys* 2019;105:254–66.